

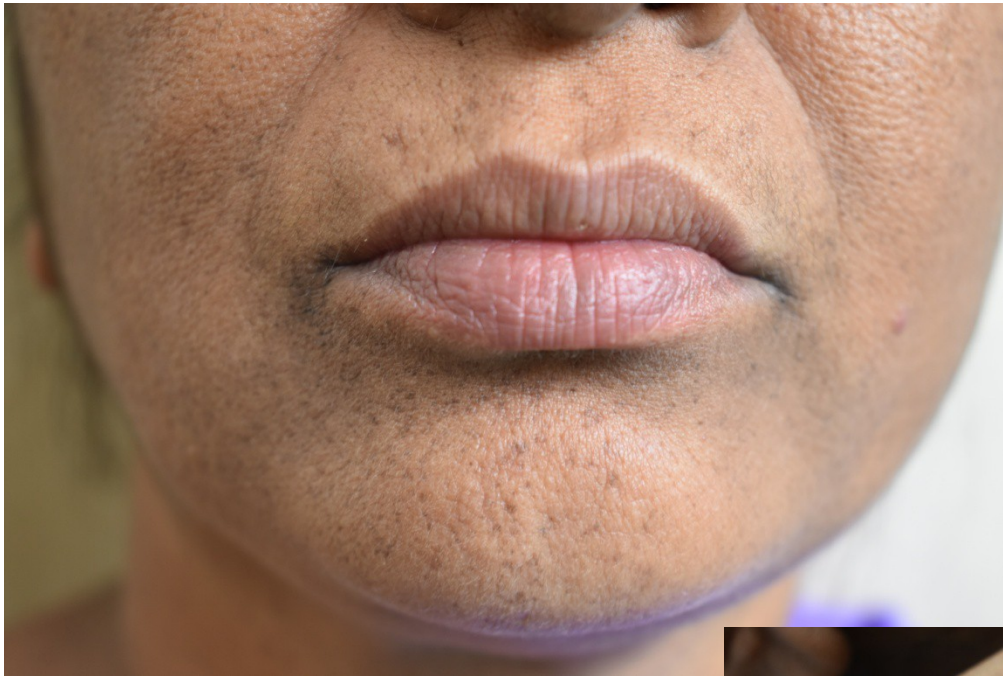MAPCON 2018 E-CASES

E-CASE 09

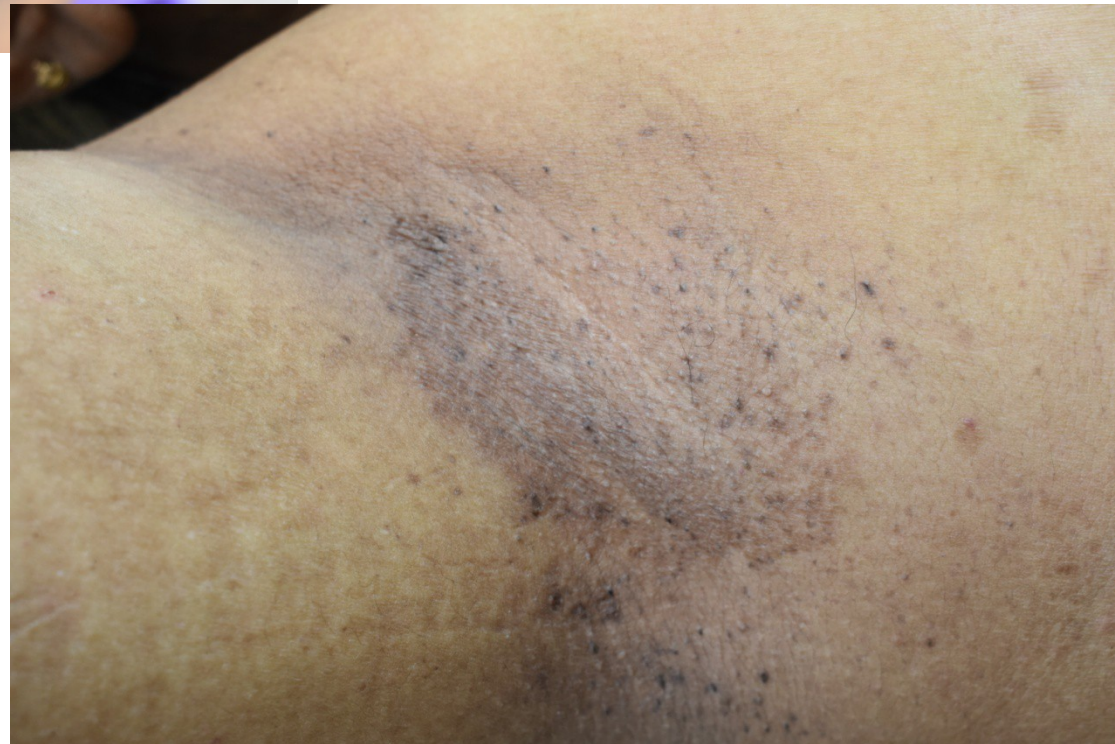H.B.T. Medical College &
Dr R.N.Cooper Hospital, Mumbai

E-CASE 09 Clinical History

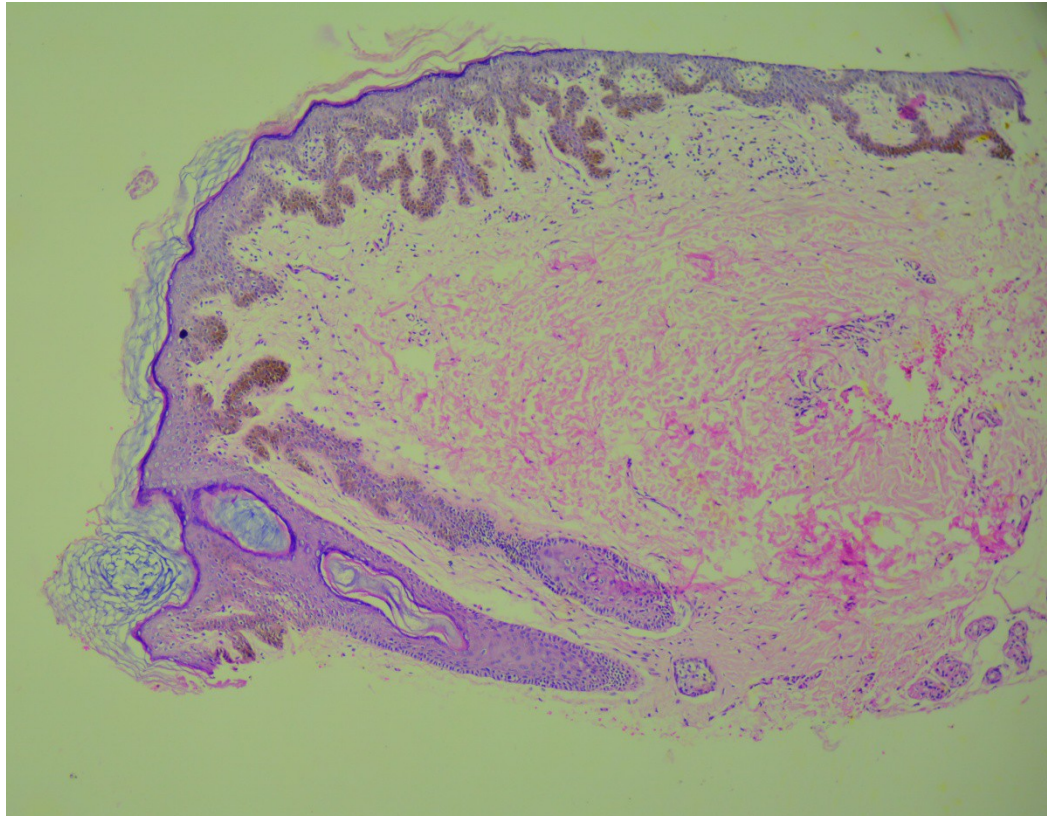
- 50 years, female , came with hyperpigmented macules and comedones on face and bilateral axillae. She underwent a skin biopsy.

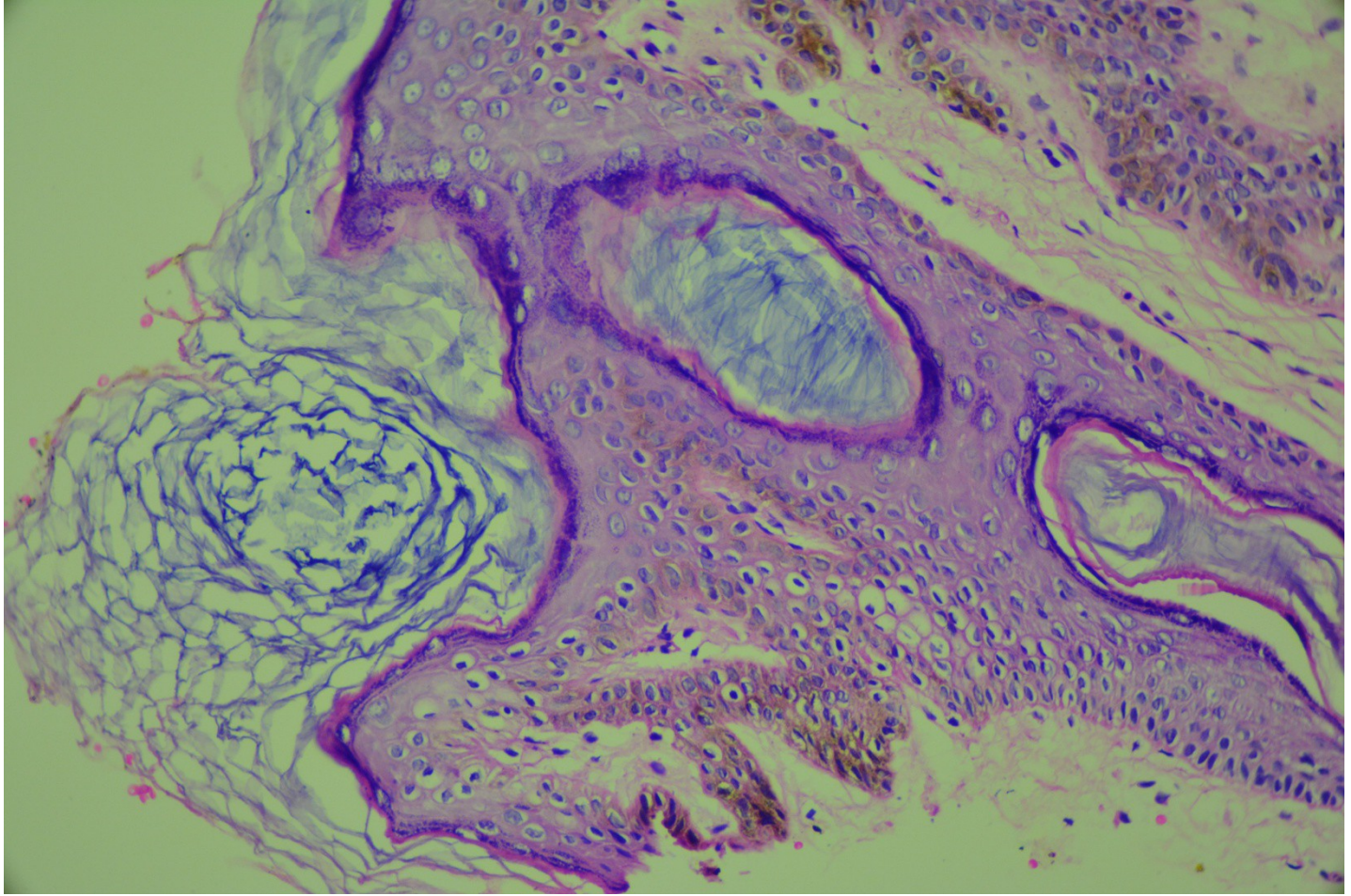


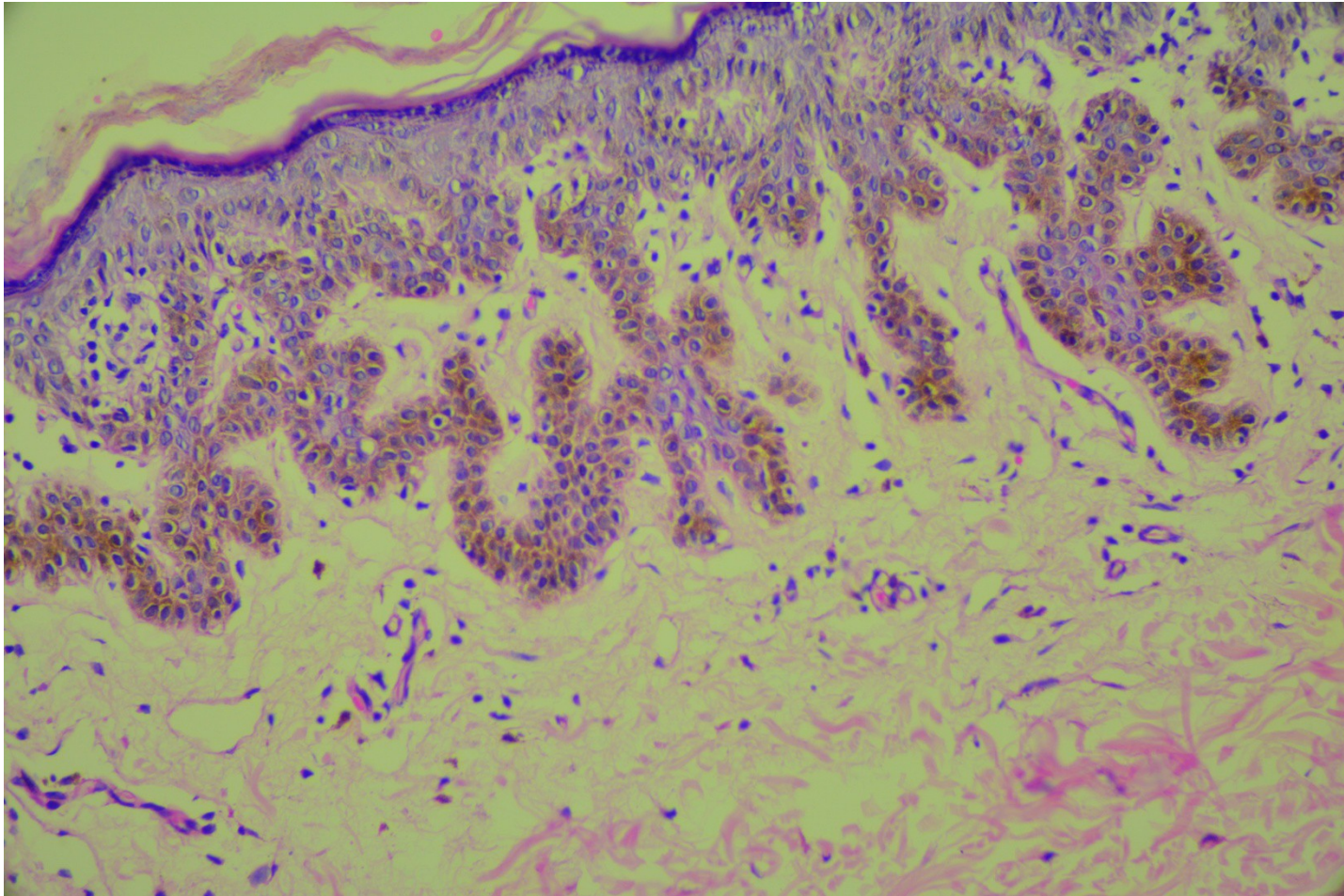
Clinical Photo



Skin Biopsy







DIAGNOSIS ??